



PATIENT

Bosley Beckham

SPECIES

Canine

BREED

Standard Poodle

SEX

MN

AGE

12 years

WEIGHT

21.9 kg

INTERPRETED BY

Remo Lobetti, BVSc,
MMedVet (Med), PhD,
Dipl. ECVIM

IMAGING PERFORMED BY

Brent Crutchfield, DVM

HOSPITAL NAME

Treasure Coast Animal
Emergency

REFERRING VET

Angela Cail

INVOICE

304207

DATE

5/12/23

PRESENTING CLINICAL SIGNS

History: Progressive weight loss. No abnormalities on previous ultrasound (9/8/22).

Physical Examination: N/A.

Urinalysis: N/A.

CBC: N/A.

Serum Biochemistry: N/A.

Radiographic Findings: N/A.

ULTRASONOGRAPHIC EXAMINATION OF THE ABDOMEN

Urinary System

Full urinary bladder with a normal thickness (0.1 cm) and appearance of the wall. Normal anechoic urine with no sediment or uroliths evident.

Normal trigone area, proximal urethra, and iliac blood vessels.

Normal iliac lymph nodes. Ureters not visualized.

Normal renal size (left 5.3 cm, left 6.1 cm), echogenic appearance, cortico-medullary differentiation, pelvis, and capsule. Small cortical cyst in the cranial pole of the right kidney.

Reproductive System

Small hypoechogenic prostate.

Adrenal Glands

Normal echogenic appearance, position, and shape. Normal size of right gland (0.65 cm), enlarged left gland 0.82 cm.

Spleen

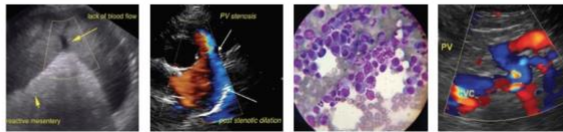
Normal size and echogenic appearance. Smooth homogenous parenchyma, regular curvilinear capsule, and normal vasculature. No inflammatory, neoplastic, infarction, or infiltrative changes evident.

Liver

Normal size, echogenic appearance, portal markings, and regular curvilinear capsule. Focal hyperechogenic nodule (2.2 cm) in the cranial left lobe. No masses evident.

Gall bladder

Full containing normal anechoic bile. Normal thickness (0.2 cm) and echogenic appearance of the wall. Normal bile duct.



PATIENT

Bosley Beckham

SPECIES

Canine

BREED

Standard Poodle

SEX

MN

AGE

12 years

WEIGHT

21.9 kg

INTERPRETED BY

Remo Lobetti, BVSc,
MMedVet (Med), PhD,
Dipl. ECVIM

IMAGING PERFORMED BY

Brent Crutchfield, DVM

HOSPITAL NAME

Treasure Coast Animal
Emergency

REFERRING VET

Angela Cail

INVOICE

304207

DATE

5/12/23

Gastrointestinal

Normal appearance of the gastro-esophageal junction, stomach, ileo-cecal junction, and colon with no loss of layering, normal wall thickness (stomach 0.29 cm, colon 0.18 cm), and no distension of the lumen. Thickening of the duodenum (0.65 cm) and small intestine (0.77 cm) with no loss of layering or distension of the lumen. Faint mucosal stippling of the small intestine. In comparison with the previous ultrasound, the thickness of the duodenum has remained static whereas there has been progressive thickening of the small intestine.

Pancreas

Normal size and echogenic appearance. Regular capsule. Normal echogenic appearance of the mesentery and fat surrounding the pancreas.

Free Abdomen

No mesenteric lymphadenomegaly.
No ascites.

ULTRASONOGRAPHIC FINDINGS

Primary findings:

- Enteropathy.
- Hepatic nodule
- Enlarged left adrenal gland.

Secondary findings:

- Renal cyst.

INTERPRETATION OF THE FINDINGS & FURTHER RECOMMENDATIONS

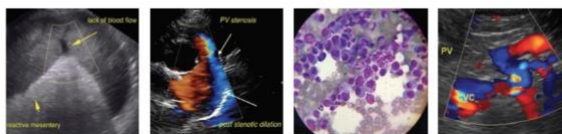
Etiologies for the enteropathy would be primary lymphangectasia, inflammatory bowel disease, parasitic enteritis, granulomatous enteritis, dietary hypersensitivity, and emerging lymphoma.

Etiologies for the hepatic nodule would be nodular hyperplasia, granuloma, organized hematoma, organized abscess, hepatoma, and neoplasia.

Etiologies for the left adrenal gland would be incidental finding, disease stress, and emerging Cushing's disease.

Further assessment would be fecal analysis, cobalamin assay, FNA cytology of the hepatic nodule, endoscopy of the upper GI tract with biopsies, and if there are compatible clinical and biochemical signs of Cushing's disease, adrenal function testing (ACTH stimulation/LDDS test).

Specific therapy would be dependent on an etiological diagnosis. Symptomatic therapy would be hypoallergenic/novel protein diet, course of fenbendazole, cobalamin supplementation, and possibly prednisolone.



PATIENT

Bosley Beckham

SPECIES

Canine

BREED

Standard Poodle

SEX

MN

AGE

12 years

WEIGHT

21.9 kg

INTERPRETED BY

Remo Lobetti, BVSc,
 MMedVet (Med), PhD,
 Dipl. ECVIM

IMAGING PERFORMED BY

Brent Crutchfield, DVM

HOSPITAL NAME

Treasure Coast Animal
 Emergency

REFERRING VET

Angela Cail

INVOICE

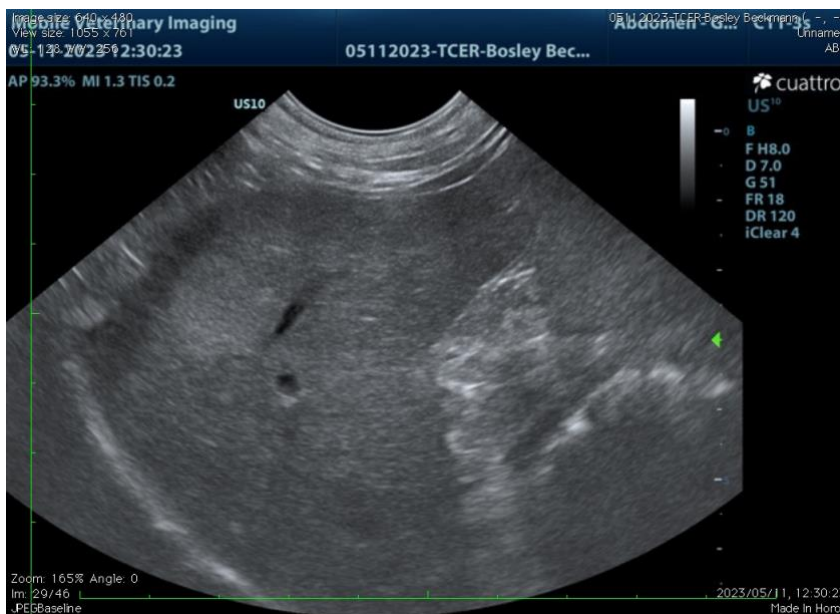304207

DATE

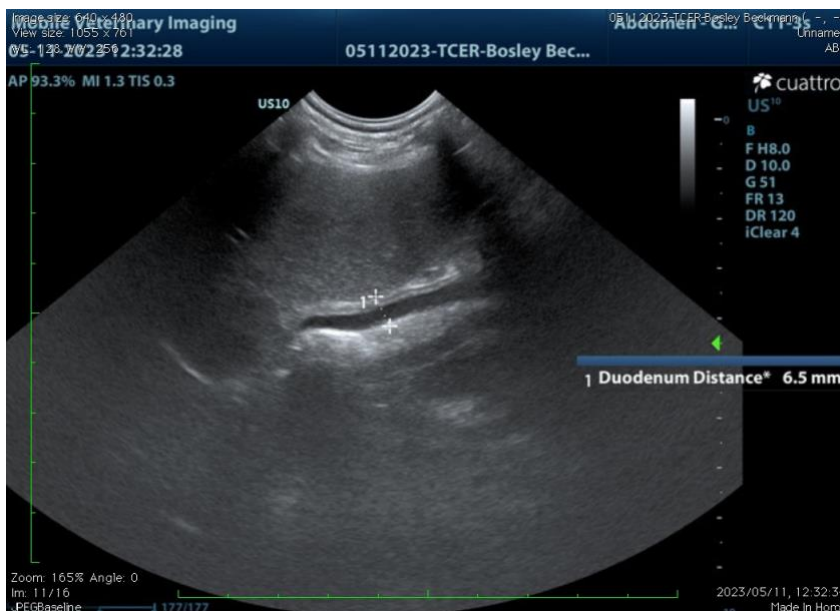5/12/23

IMAGES

Liver



Duodenum





PATIENT

Bosley Beckham

SPECIES

Canine

BREED

Standard Poodle

SEX

MN

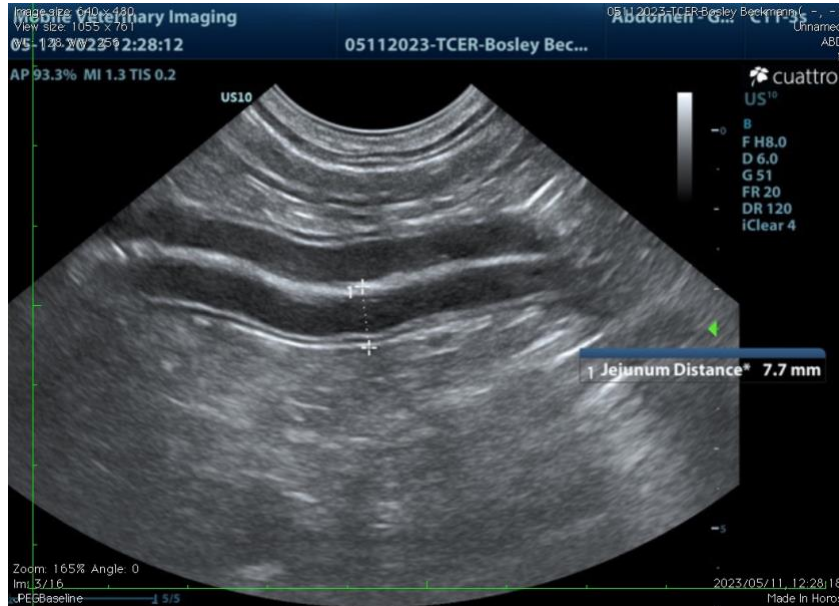AGE

12 years

WEIGHT

21.9 kg

Jejunum



INTERPRETED BY

Remo Lobetti, BVSc,
 MMedVet (Med), PhD,
 Dipl. ECVIM

The information and recommendations provided are based on the images presented by the referring veterinarian. No evaluation can be communicated regarding pathology that was not visible in the image/video clips provided.

Thank you for this referral. If the clinical or image interpretation does not parallel your findings or if I can be of any further assistance please contact me.

Remo Lobetti, BVSc, MMedVet (Med), PhD, Dipl. ECVIM (Internal Medicine)
 remo.lobetti@sonopath.com

IMAGING PERFORMED BY

Brent Crutchfield, DVM

HOSPITAL NAME

Treasure Coast Animal
 Emergency

REFERRING VET

Angela Cail

INVOICE

304207

DATE

5/12/23